

Single implant restoration and adhesive bridge for anterior teeth: a case report

Edy Machmud,* Maqhfirah Amiruddin

Abstract

Objective: The aim of this case report restore healthy tooth function so that patients can chew food properly, so the method of implant placement is a good choice for patients with tooth loss. The adhesive bridge denture treatment aims to restore a missing tooth.

Methods: A 21 years old female patient came to Dental Hospital Hasanuddin University with complaints of difficulty chewing food because her posterior teeth were missing which had been removed +/-1 year ago and wanted to make permanent dentures the woman used removable dentures on the anterior teeth because her anterior

teeth missing around +/-5 years ago due to an accident and want to replace the removable denture with a permanent denture.

Results: Bone density obtained from ct-scan radiographic greatly determines this treatment choice, the higher the bone density, the better the prognosis produced.

Conclusion: Use of dentures with implant support for posterior mandibular teeth and adhesive bridge dentures for maxillary anterior teeth provides satisfaction for patients because it can overcome aesthetic problems and improve good phonetic and masticatory functions.

Keywords: Adhesif Bridge, Bone Density, Ct-scan, Dental Implant

Cite this Article: Machmud E, Amiruddin M. 2019. Single implant restoration and adhesive bridge for anterior teeth: a case report. *Journal of Case Reports in Dental Medicine*. 1(2): 49-52. DOI: [10.20956/jcrdm.v1i2.92](https://doi.org/10.20956/jcrdm.v1i2.92)

Department of Prosthodontics,
Faculty of Dentistry, Hasanuddin
University, Makassar, Indonesia

Introduction

Posterior tooth loss causes the masticatory function to be disrupted. Along with advances in technology in the world of dentistry, dentures with implant support are a very popular treatment alternative today that can produce good long-term care. The anterior tooth loss can result in severe emotional trauma in the patient, this is a condition that disrupts aesthetics and functions of mastication and phonetics. The use of adhesive bridges is a solution to replace lost anterior teeth which is indicated for young patients who have a mild occlusion load.¹⁻⁴

The adhesive bridge denture treatment aims to restore a missing tooth. The indication of adhesive bridge denture treatment is a mild contact of occlusion, young patients and good oral hygiene.

Case Report

A 21 years old female patient came to Dental Hospital Hasanuddin University with complaints of difficulty chewing food because her posterior teeth were missing which had been removed +/-1 year ago and wanted to make permanent dentures. The woman also used removable dentures on the anterior teeth because her anterior teeth missing around +/-5 years ago due to an accident and want to replace the removable denture with a permanent denture.

On first visit doing filling status and patient signed an informed consent and making study

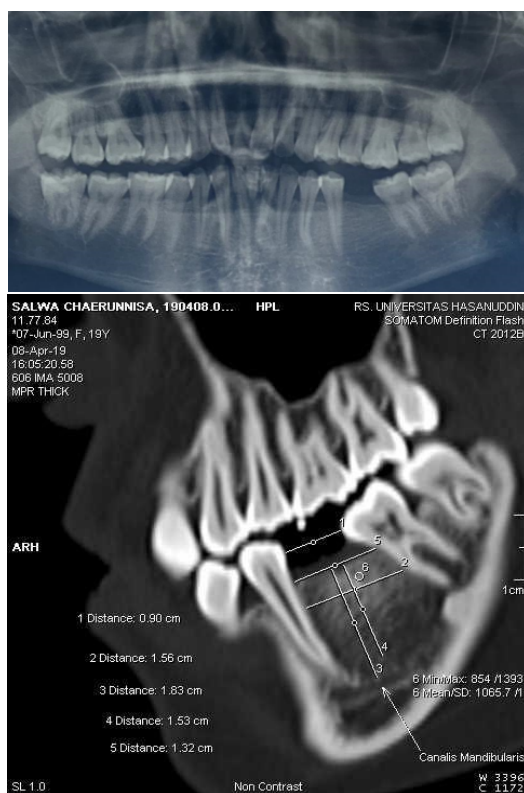


Figure 1 Panoramic View, some aspects of Ct-Scan view showed that the position and distance measurement of mesiodistal and buccolingual in edentulous area 36. This picture also shows the length of alveolar crest to canalis mandibularis and showed bone density measurements

*Correspondence to:
machmudeddy@gmail.com

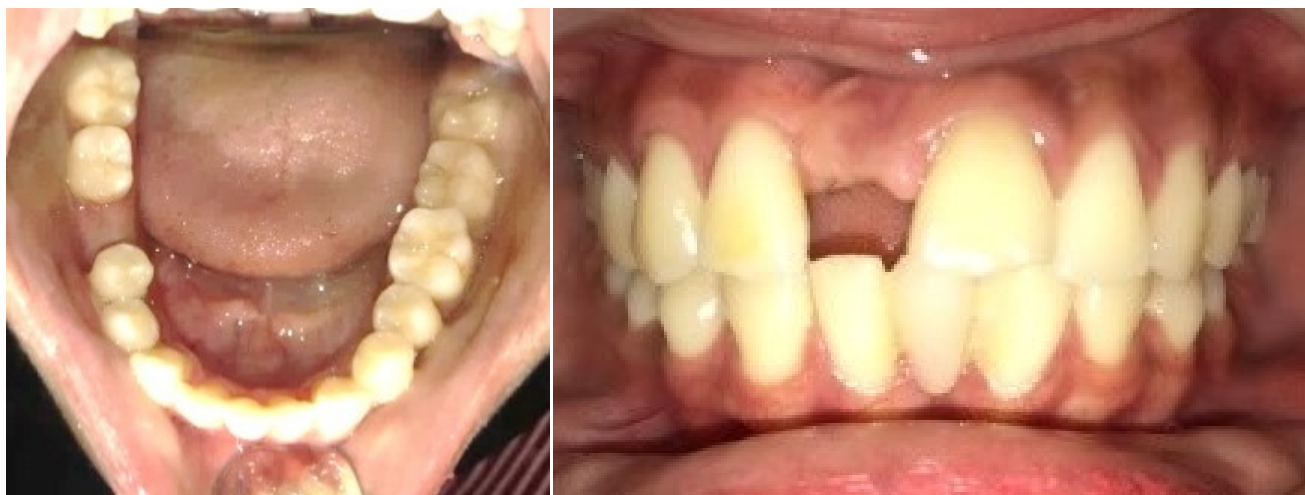

Figure 2 Intra Oral

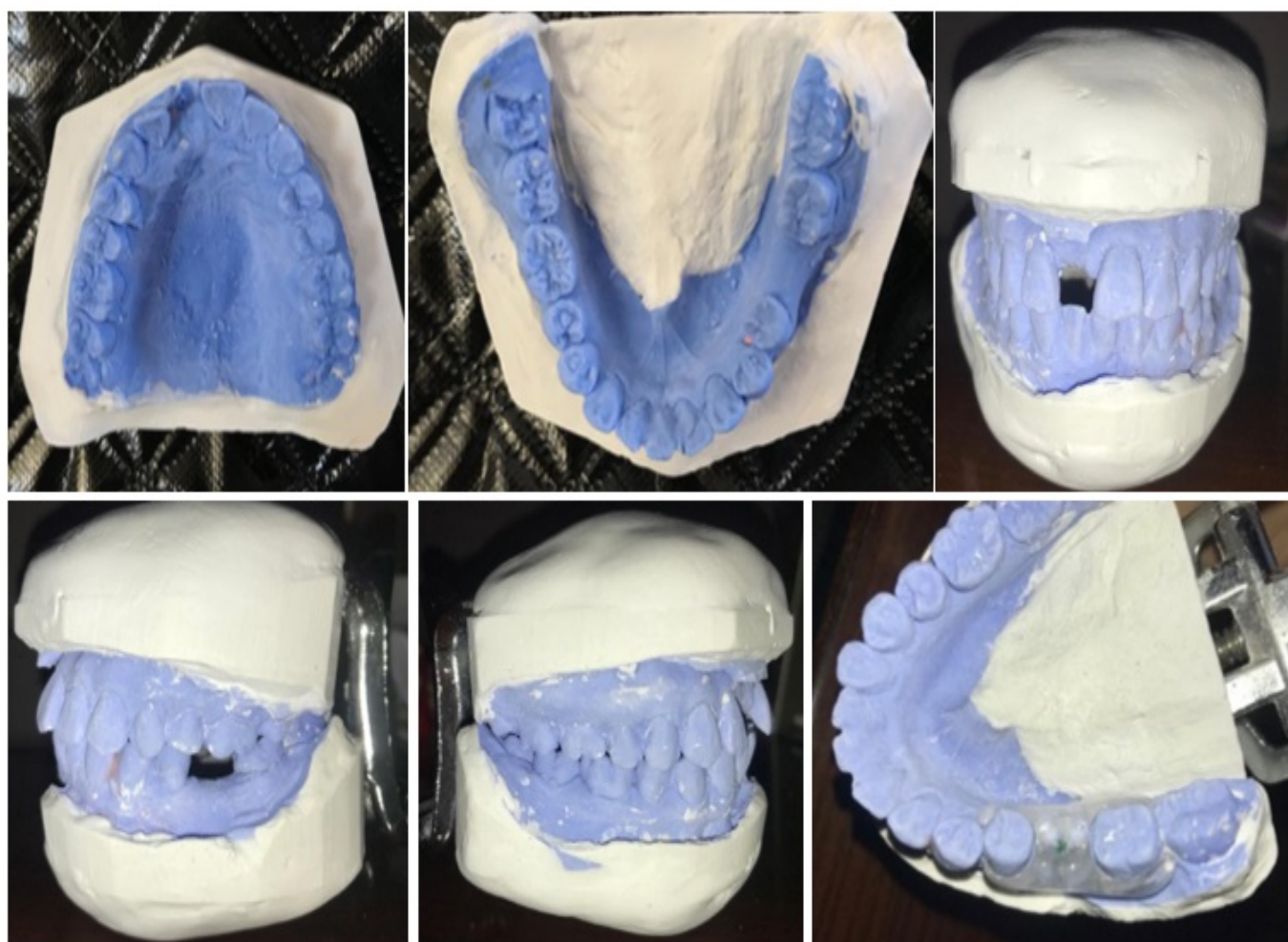


Figure 3 Study Cast and Surgical Template

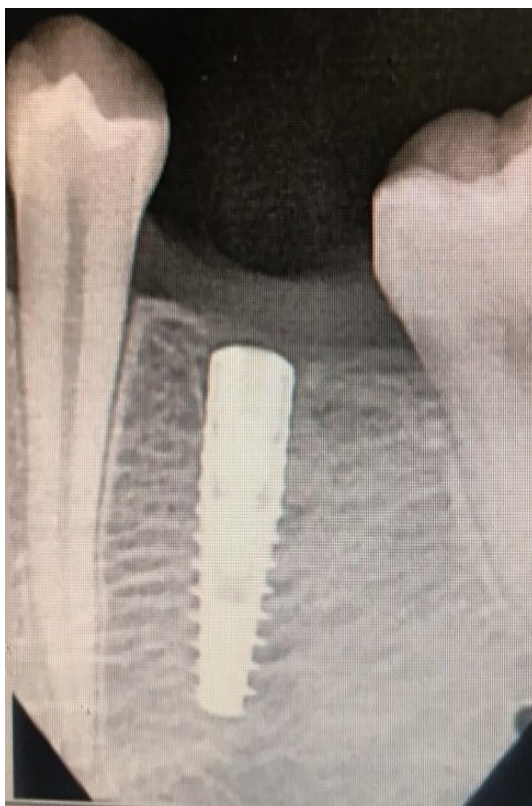

Figure 4 Implantation regio 36

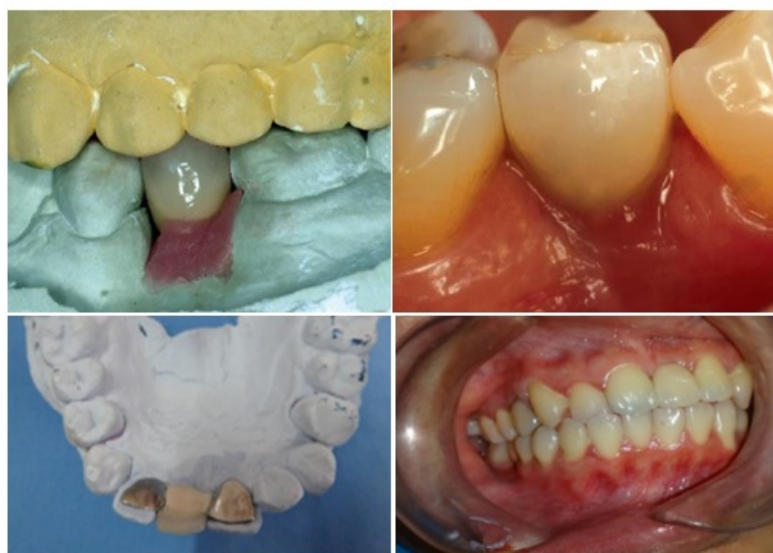

Figure 5 Supra structure 36, adhesive bridge, intra oral after insertion adhesif bridge

casts, then proceed with making a surgical casts, then proceed with making a surgical template. After that, a ct-scan was performed to determine the size of the implant that matches the size of the available bone.

The second visit, carried out the edentulous 36 implantation process using implants measuring 3.7mm in diameter and 12 mm in length with

the EZ Dent-I IDI brand. Third visit, tooth color the EZ Dent-I IDI brand. Third visit, tooth color selection with shade guide, and preparation of the palatal part of abutment teeth 12 and 21 was made for bridge adhesive in edentulous teeth 11. Two months later, double impression was performed for the manufacture of supra structural teeth.

Discussion

The advantage of dental implants is that they closely resemble natural teeth because they are embedded in the tissue so they can support aesthetics, protection of adjacent teeth and the development of self-confidence. The successful insertion of dental implants in patients begins with a method of implant placement that is good, does not cause pain and the obtained final results are teeth that are better aesthetically. Bone density obtained from ct-scan radiographic photographs greatly determines this treatment choice, the higher the bone density, the better the prognosis produced. This method of treatment aims to restore healthy tooth function so that patients can chew food properly, the method of implant placement is a good choice for patients with tooth loss. The adhesive bridge denture treatment aims to restore a missing tooth. The indication of adhesive bridge denture treatment is a mild contact of occlusion, young patients and good oral hygiene.⁵

Conclusion

The use of dentures with implant support for posterior mandibular teeth and adhesive bridge dentures for maxillary anterior teeth provides satisfaction for patients because it can overcome aesthetic problems and improve good phonetic and masticatory functions.

Acknowledgment

None.

Conflict of Interest

The authors report no conflict of interest.

References

1. Misch CE. Dental Implant Prosthetics. 2nd ed. Mosby Co; 2015.
2. Babbush CA. Dental implant principle and practice; 1st ed. WB Saunders Company. United States of America. 1991

3. Assraf M, Gharbyeh AZ. Screw-retained crown restorations of single implants: a step-by-step clinical guide. *Eur Dent J* 2014;8: 563-570.
4. Rosenstiel SF, Land MF, Fujimoto J, Contemporary fixed Prosthodontics. 4th ed. St.Louis, Mosby Co, 2006.
5. Habar ID, Ardiansyah M, Surya ES, et al. Prosthodontic rehabilitation after traumatic anterior teeth and anodontia of mandibular right second premolar: a case report. *J Dentomaxillofac Sci* 2018;3: 129-131.



This work is licensed under a Creative Commons Attribution